ANTICANCER RESEARCH *21:* 2895-2900 (2001)

Phase I Clinical Trial of Curcumin, a Chemopreventive Agent, in Patients with High-risk or Pre-malignant Lesions

ANN-LII CHENG[1,2], CHIH-HUNG HSU[2], JEN-KUN LIN[3], MOW-MING HSU[5], YUNN-FANG HO[4], TZUNG-SHIAHN SHEN[5], JENQ-YUH KO[5], JAW-TOWN LIN[1], BOR-RU LIN[1], MING-SHIANG WU[1], HSIN-SU YU[10], SHIOU-HWA JEE[9], GWO-SHING CHEN[10], TZER-MING CHEN[6], CHI-AN CHEN[6], MING-KUEN LAI[7], YEONG-SHIAU PU[7], MIN-HSIUNG PAN[3], YING-JAN WANG[3], CHIEN-CHENG TSAI[8] and CHANG-YAO HSIEH[6]

Departments of [1]Internal Medicine, [2]Oncology, [3]Biochemistry, [4]Pharmacy, [5]Otorhinolaryngology, [6]Gynecology, [7]Urology, [8]Pathology and [9]Dermatology, National Taiwan University College of Medicine, Taipei; Department of [10]Dermatology, Kaohsiung Medical College, Kaohsiung, Taiwan, R.O.C..

Abstract. *Curcumin (diferuloylmethane), a yellow substance from the root of the plant Curcuma longa Linn., has been demonstrated to inhibit carcinogenesis of murine skin, stomach, intestine and liver. However, the toxicology, pharmacokinetics and biologically effective dose of curcumin in humans have not been reported. This prospective phase-I study evaluated these issues of curcumin in patients with one of the following five high-risk conditions: 1) recently resected urinary bladder cancer; 2) arsenic Bowen's disease of the skin; 3) uterine cervical intra-epithelial neoplasm (CIN); 4) oral leucoplakia; and 5) intestinal metaplasia of the stomach. Curcumin was taken orally for 3 months. Biopsy of the lesion sites was done immediately before and 3 months after starting curcumin treament. The starting dose was 500 mg/day. If no toxicity ≥ grade II was noted in at least 3 successive patients, the dose was then escalated to another level in the order of 1000, 2000, 4000, 8000, and 12000 mg/day. The concentration of curcumin in serum and urine was determined by high pressure liquid chromatography (HPLC). A total of 25 patients were enrolled in this study. There was no treatment-related toxicity up to 8000 mg/day. Beyond 8000 mg/day, the bulky volume of the drug was unacceptable to the patients. The serum concentration of curcumin usually peaked at 1 to 2 hours after oral intake of crucumin and gradually declined within 12 hours. The average peak serum concentrations after taking 4000 mg, 6000 mg and 8000 mg of curcumin were 0.51 ± 0.11 μM, 0.63 ± 0.06 μM, and 1.77 ± 1.87 μM, respectively. Urinary excretion of curcumin was undetectable. One of 4 patients with CIN and 1 of 7 patients with oral leucoplakia proceeded to develop frank malignancies in spite of curcumin treatment. In contrast, histologic improvement of precancerous lesions was seen in 1 out of 2 patients with recently resected bladder cancer, 2 out of 7 patients of oral leucoplakia, 1 out of 6 patients of intestinal metaplasia of the stomach, 1 out of 4 patients with CIN and 2 out of 6 patients with Bowen's disease. In conclusion, this study demonstrated that curcumin is not toxic to humans up to 8000 mg/day when taken by mouth for 3 months. Our results also suggest a biologic effect of curcumin in the chemoprevention of cancer.*

Correspondence to: Dr. Ann-Lii Cheng, Department of Internal Medicine and Department of Oncology, National Taiwan University Hospital, No. 7, Chung-Shan South Road, Taipei, Taiwan, R.O.C.. Fax: 886-2-2371-1174. e-mail: andrew@ha.mc.ntu.edu.tw

Key Words: Curcumin, chemoprevention, phase-I clinical trial, pharmacokinetics.

Curcumin, a diferuloylmethane (Figure 1), is a yellow substance extracted from the root of the plant *Curcuma longa* Linn.. It is a common food additive used as both a spice and a coloring agent and is the yellow substance of curry. In India and China, curcumin has long been used as a medicinal herb. Recently, curcumin was suggested to have a chemopreventive effect against cancers (1, 2).

In vitro studies have indicated that curcumin inhibits several TPA-induced signal transduction pathways (3-5). We have previously demonstrated that curcumin inhibits TPA-induced activation of protein kinase C, formation of 8 hydroxy-deoxyguanosine and transactivation of c-jun/Ap-1 (6-8). Evidence suggests that curcumin acts on stages of initiation, promotion and progression of carcinogenesis (9-12).

In animal studies, curcumin was demonstrated to have a chemopreventive effect on murine carcinogenesis of skin cancer, gastric cancer, oral cancer and intestinal cancer (13-17). We recently demonstrated that curcumin inhibits diethylnitrosamine–induced hepatocellular carcinoma in mice (18). Despite its many beneficial biological and pharmacological effects, curcumin is not toxic to small and large animals, even at very large doses (19, 20). These lines of evidence indicate that curcumin is a potentially ideal agent for the chemoprevention of human cancers. However, the toxicology, pharmarcokinetics and biologically-active dose of curcumin in humans have not been previously reported. This phase-I study assessed the toxicity and chemopreventive

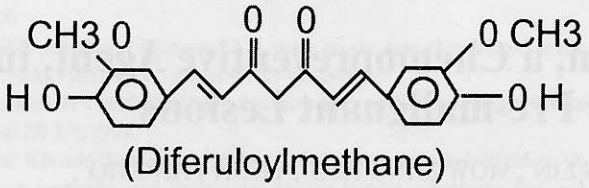

Figure 1. *The chemical structure of curcumin (diferuloylmethane).*

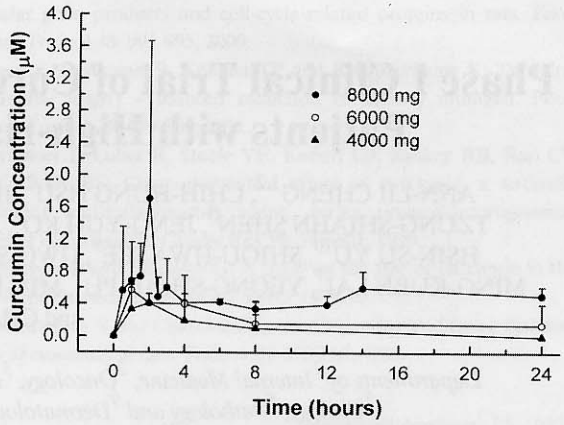

Figure 2. *The serum concentration of curcumin in patients taking 4000, 6000, or 8000 mg/day of curcumin.*

effect of various doses of curcumin in patients at high risk of cancers. The biologically active dose of curcumin and the preliminary pharmacokinetics were also assessed in these patients.

Patients and Methods

Patients. This study was conducted from July 1995 to December 1998 at National Taiwan University Hospital and Kaohsiung Medical College, Taiwan. To be eligible for this phase-I clinical trial, the patients were required to have one of the following five high-risk conditions: 1. recently-resected urinary bladder cancer; 2. arsenic Bowen's disease of the skin, which is an endemic disease in southern Taiwan; 3. uterine cervical intraepithelial neoplasia (CIN); 4. oral leucoplakia, which is commonly seen in local betel-nut chewers; or 5. intestinal metaplasia of the gastric mucosa. Patients were excluded if they did not have normal cardiac, hepatic (bilirubin < 1.5 mg/dl, ALT < 1.2 x normal), renal (creatinine < 1.5 mg/dl, BUN < 25 mg/dl) and hematopoietic (WBC > 4000/mm^3, platelet > 100,000/mm^3) function, or did not give signed informed consent for participation in the study. This clinical trial was approved by the ethics committee of National Taiwan University Hospital.

Drug. Diferuloylmethane was manufactured by chemical methods (Yung-Shin Pharmaceutical Co. Taiwan). The purity was 99.3%. Each tablet contained 500 mg of curcumin.

Scheme of clinical trial. Curcumin was taken once in the morning with empty stomach. If no toxicity ≥ grade II developed, curcumin was taken for 3 months. Since a previous small-series human study used 500 mg/day for 7 days without observing any toxicity and a common diet in India may contain as much as 100 mg/day of curcumin, 500 mg/day was chosen as the starting dose in this study (21). The dosage of level 1, 2, 3, 4, 5, 6 was 500, 1000, 2000, 4000, 8000, and 12000 mg/day, respectively. New patients were enrolled into the next higher dose level as soon as at least 3 patients at a given level had completed the 3-month treatment and no more than one patient had experienced any ≥ grade II toxicity.

The patients received regular follow up at outpatient clinics including routine physical examination, weekly hemogram and biweekly blood electrolytes and biochemistry study. Electrocardiography, bone marrow examination and imaging studies were done if indicated.

Measurement or evaluation of the indicator lesions was done at least every 4 weeks. The tissue samples from the indicator lesions were taken before and at the completion of the 3-month treatment with curcumin. Routine histopathology was examined and the remaining samples were kept for further studies of intermediate biological markers relevant to each high-risk lesion.

Pharmacokinetic study. The pharmacokinetic study was performed in normal volunteers and selected patients who agreed to the procedure. Blood samples of 8 ml each were collected from the antecubital vein just prior to ingestion and at 0, 0.5, 1, 1.5, 2, 2.5, 3, 4, 6, 8, 12, 14 and 24 hours after drug administration. The plasma fraction was separated from blood immediately, placed in a freezer within 30 minutes of collection and kept at -30°C in labeled vials until assayed.

Urinary samples were collected during 0-2, 2-4, 4-8 and 8-24 hour periods after ingestion of curcumin. After measuring the urine volumes and pH values, a 10 ml aliquot of each sample was retained and stored at -30°C until assayed.

High pressure liquid chromatography (HPLC) was performed with a Jasco liquid chromatograph equipped with a PU-980 intelligent pump, a variable wavelength UV-975 UV/Vis detector and an integrator Waters 745B Data Module. The procedure described by Cooper *et al.* was used for the determination of curcuminoid on a C18 column (150x3.9 mm, 5-μM particle size, Waters) (22). The mobile phase was 40% THF and

Figure 3. *Illustrative examples of histologic improvement in lesions after curcumin treatment. (A1) Magnified x 200, CIN-1 of uterine cervix (case 2, level 1) shows abundant koilocytes (arrow). The nuclei of the epithelial cells show marked pleomorphism and loss of polarity. Mitoses are present (arrow head). (A2) Magnified x 200, only mild chronic cervicitis is observed. (B1) Magnified x 100, specimen from a patients with Bowen's disease (case 5, level 1) shows acanthosis, loss of cell polarity and marked cellular dysplasia. Pleomorphic large cells with hyperchromatic nuclei are shown in the insert (magnified x 200). (B2) Almost normal skin was noted after treatment (magnified x 100). (C1) Magnified x 200, specimen from a patients with intestinal metaplasia of the stomach (case 11, level 2) shows abundant goblet cells (arrow). Cross-section of the respresentative glands are shown in the insert. (C2) Milder degree of intestinal metaplasia with decreased number of goblet cells was seen after treatment. Cross-section of the respresentative glands are shown in the insert. (D1) Magnified x 100, post-operative urinary bladder cancer (case 16, level 3) shows epithelial dysplasia with large cells and marked nuclear atypia (insert). (D2) Significantly less atypia was observd after treatment. (E1) Magnified x 100, oral leucoplakia (case 18, level 4) shows marked squamous hyperplasia with elongated, broader rete ridges (insert). (E2) Markedly decreased hyperplasia was noted after treatment.*

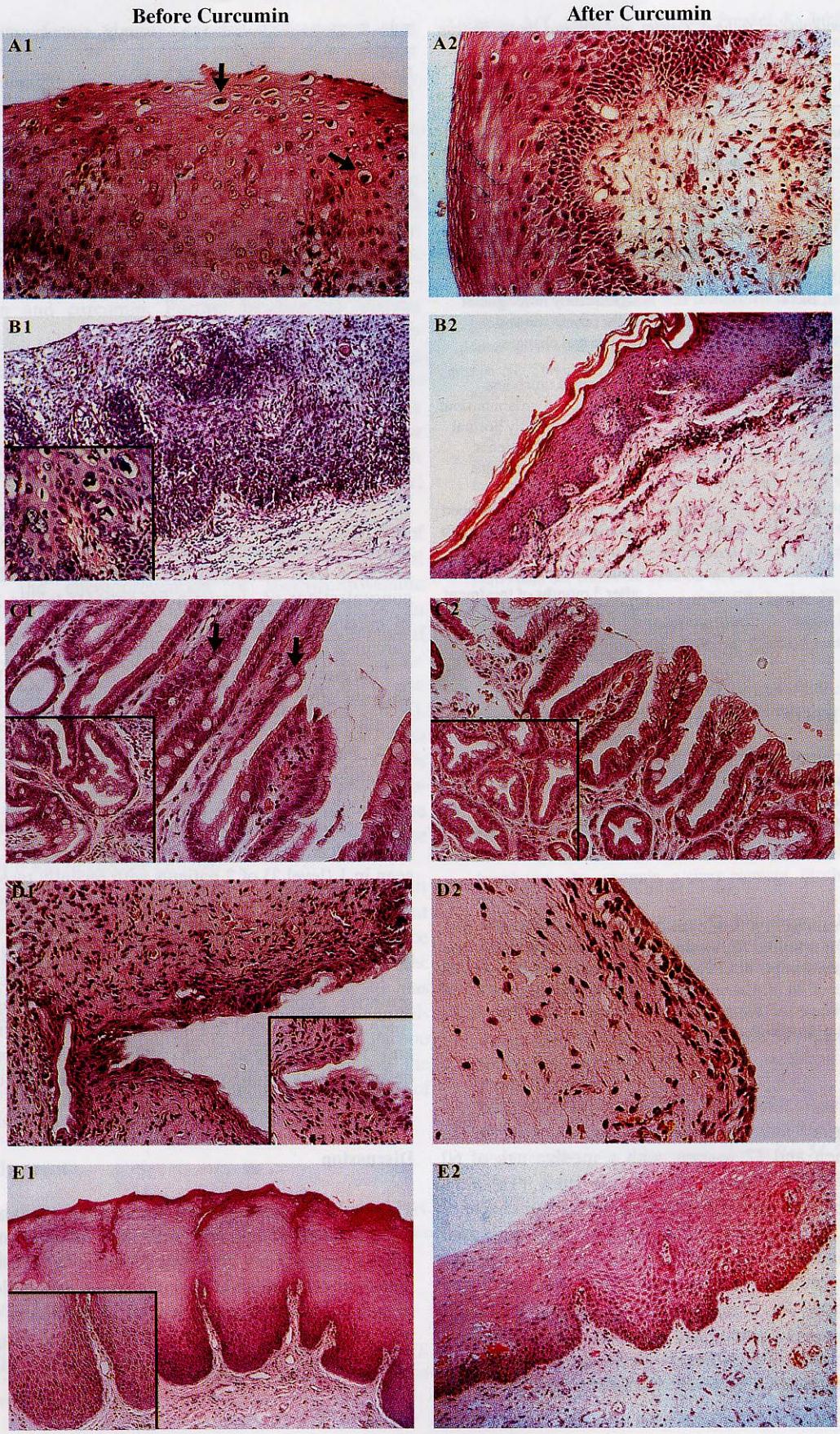

Figure 3.

Table I. *Clinicopathological features, toxicity, and repeated biopsy findings of the patients.*

			After curcumin treatment	
Level	No.	Pathological features	Toxicity	Pathology of re-biopsy
I	6	OL:1, CIN:1, BC:1, IM :2 BD:1	None	CIN-1 and BD became normalized; no interval changes were found in other 4 cases.
II	6	OL:1, CIN:2, IM :2, BD:1	None	One IM patient showed significantly fewer goblet cells; others showed no interval changes.
III	4	IM :2, BC:1 BD:1	None	BC showed much less dysplasia and inflammation; BD became nearly normal skin; No other patients showed interval change.
IV	6	OL:4, CIN:1	None	One CIN patient developed adenocarcinoma at 1 month of treatment. One of 4 OL patients developed SCC after 3 months of treatment. Two of 4 OL patients showed significant decrease of hyperkeratosis and parakeratosis.
V	3	OL:1, BD:2	None	No interval change was observed in all 3 cases.

Re-biopsy, repeated biopsy; OL, Oral leucoplakia; CIN, uterine cervical intraepithelial neoplasia; BC, urinary bladder cancer; IM, intestinal metaplasia of stomach; BD, Bowen's disease; SCC, squamous cell carcinoma.

60% water containing 1% citric acid adjusted to pH 3.0 with concentrated KOH solution. The system was run isocratically at the flow rate of 1 ml/minute. Sample detection was performed at 420 nm with an injection volumes of 20 μl. Calibration curves over the range of 0.2-20 μM were established for the quantitation of curcumin. This HPLC method offered a detection limit of 5 ng/ml.

Results

Clinicopathological features of the patients. A total of 25 patients, 13 men and 12 women, with a median age of 60 years (range: 36-77) were enrolled in the study (Table I). There were 2 patients with recently resected bladder cancer, 7 patients with oral leucoplakia, 6 patients with intestinal metaplasia of the stomach, 4 patients with CIN and 6 patients with Bowen's disease. Except for one of the 2 patients (Table I), who developed frank malignancies during the treatment period and thus discontinued the use of curcumin, all other patients completed the 3-month treatment regimen. No toxicity was observed up to level 5 (8000 mg/day). However, further escalation to level 6 (12,000 mg/day) was not possible because the bulky volume of the tablets was not acceptable to the patients.

Table II. *The pharmacokinetic parameters of curcumin treatment.*

Dose (mg/day)	No.	AUC_{0-24} (nMole•h/ml)	Cmax (μM)	Tmax (hr)
4000	5	2.55±1.76	0.51±0.11	1.67±0.58
6000	4	4.80±4.49	0.64±0.06	2.00±1.73
8000	2	13.74±5.63	1.77±1.87	1.75±0.35

Pharmacokinetic study. The serum concentrations of curcumin are illustrated in Figure 2. The serum concentation of curcumin usually peaked at 1-2 hours after oral intake, and gradually declined within 12 hours. The AUC_{0-24} was evaluated by the linear trapezoidal method, and the values of observed Cmx and Tmax are shown in Table II. The serum concentrations of curcumin for patients taking 500-2000 mg of curcumin were barely detectable (data not shown). No curcumin could be detected in the urine.

Pharmacokinetic studies were repeated in two selected patients after they had taken curcumin for more than one month. The results were the same as the values at the first time, suggesting that there is no multi-dose effect for oral curcumin.

Histological examinations before and after curcumin treatment. Histological improvement of the precancerous lesions was seen in 1 (level 3) of 2 patients with recently resected bladder cancer, 2 (both level 4) of 7 patients with oral leucoplakia, 1 (level 2) of 6 patients with intestinal metaplasia of the stomach, 1 (level 1) of 4 patients with CIN and 2 (level 1 and 3) of 6 patients with Bowen's disease (Table I). Representative examples and the details of histological improvement are described in Figure 3. One of 4 patients with CIN and 1 of 7 patients with oral leucoplakia proceeded to develop frank malignancies despite the use of curcumin (Table I).

Discussion

This study has demonstrated that oral curcumin is not toxic to humans even at the very high dose of 8000 mg/day. This finding supports the results of previous animal studies which indicated that curcumin does not cause noticeable damage or sequellae in the organs of small or large animals (19,20). The present study has also provided evidence suggesting that curcumin has a chemopreventive effect against human cancers.

The results of our pharmacokinetic study suggest that curcumin is not adequately absorbed from the gastrointestinal tract. The peak serum concentration of curcumin was only 1.77 μM even at the highest dose of 8000 mg/day. However, the results of our recent animal study indicate that the metabolic pathways of curcumin may be more complicated than can be reflected in the current simple human pharmacokinetic study. In that study (23), we demonstrated that treatment of blood plasma with ß-glucuronidase resulted in a decrease in the concentration of two major conjugates of curcumin, and with concomitant appearance of tetrahydrocurcumin and curcumin. Further biochemical analysis suggested that curcumin was rapidly biotransformed to dihydrocurcumin and tetrahydrocurcumin, and that these compounds were later converted to mono-glucuronide conjugates (23). Since some of these metabolites may retain the pharmarologic properties of curcumin, the relatively low serum concentration of crucumin in our patients may not necessarily reflect the total beneficial biologic activity of oral curcumin.

Futher evidence for the presence of adequate bioactivity of orally taken curcumin has been gathered from other animal studies of the chemoprevention of diethylnitrosamine (DEN)–induced murine hepatocellular carcinoma (18,24). In these studies, curcumin-containing diets effectively inhibited DEN-induced murine acute hepatitis and hepatocarcinogenesis, and hence indicating that curcumin might have been adequately absorbed from the gastrointestinal tract (18,24). The biological activity of oral curcumin has been demonstrated in several other murine studies (25,26). It is noteworthy that previous work on of the murine pharmacokinetic studies of orally taken curcumin also reported that the serum concentration of curcumin was low and the urine concentration was neglegible (27,28).

In this study, we observed histologic improvement in 7 out of 25 patients with various high-risk and pre-malignant lesions. A dose-dependent effect was not observed since histological improvement was seen at almost all dose levels. However, the possibility of spontaneous remission or site bias due to repeated biopsy cound not be totally excluded in this single-arm study. Further phase IIb studies with placebo control for individual lesions are needed to comfirm the findings of this study. The recommended oral dose of curcumin for future phase II studies is 6,000-8,000 mg/day.

Acknowledgement

This work was supported by grants (NSC84-2622-B-002-007, NSC85-2622-B-002-011, NSC87-2622-B-002-002) of the National Science Council, Taipei, Taiwan, Republic of China.

References

1 Kelloff GJ, Hawk ET, Karp JE, Crowell JA, Boone CW, Steele VE, Lubet RA and Sigman CC: Progress in clinical chemoprevention. Semin Oncol *24:* 241-252, 1997.

2 Huang MT, Newmark HL and Frenkel K: Inhibitory effects of curcumin on tumorigenesis in mice. J Cell Biochem Suppl *27:* 26-34, 1997.

3 Lu YP, Chang RL, Lou YR, Huang MT, Newmark HL, Reuhl KR and Conney AH: Effect of curcumin on 12-O-tetradecanoylphorbol-13-acetate- and ultraviolet B light-induced expression of c-Jun and c-Fos in JB6 cells and in mouse epidermis. Carcinogenesis *15:* 2363-2370, 1994.

4 Kakar SS and Roy D: Curcumin inhibits TPA induced expression of c-fos, c-jun and c-myc proto-oncogenes messenger RNAs in mouse skin. Cancer Le *87:* 85-89, 1994.

5 Nakamura Y, Ohto Y, Murakami A, Osawa T and Ohigashi H: Inhibitory effects of curcumin and tetrahydrocurcuminoids on the tumor promoter-induced reactive oxygen species generation in leukocytes in vitro and *in vivo.* Jpn J Cancer Res *89:* 361-370, 1998.

6 Lin JK, Chen YC, Huang YT and Lin-Shiau SY: Suppression of protein kinase C and nuclear oncogene expression as possible molecular mechanisms of cancer chemoprevention by apigenin and curcumin. J Cell Biochem Suppl *28/29:* 39-48, 1997.

7 Shih CA and Lin JK: Inhibition of δ-hydroxydeoxyguanosine formation by curcumin in mouse fibroblastic cells. Carcinogenesis *14:* 709-712, 1993.

8 Huang TS, Lee SC and Lin JK: Suppression of c-Jun/AP-1 activation by an inhibitor of tumor promotion in mouse fibroblast cells. Proc Natl Acad Sci U.S.A *88:* 5292-5296, 1991.

9 Huang MT, Wang ZY, Georgiadis CA, Laskin JD and Conney AH: Inhibitory effects of curcumin on tumor initiation by benzo[a]pyrene and 7,12-dimethylbenz[a]anthracene. Carcinogenesis *13:* 2183-2186, 1992.

10 Shalini VK and Srinivas L: Lipid peroxide induced DNA damage: protection by turmeric (*Curcuma longa*). Mol Cell Biochem 77: 3-10, 1987.

11 Chen HW and Huang HC: Effect of curcumin on cell cycle progression and apoptosis in vascular smooth muscle cells. Br J Pharmacol *124:* 1029-1040, 1998.

12 Sikora E, Bielak-Zmijewska A, Piwocka K, Skierski J and Radziszewska E: Inhibition of proliferation and apoptosis of human and rat T lymphocytes by curcumin, a curry pigment. Biochem Pharmacol 54: 899-9071997.

13 Huang MT, Smart RC , Wong CQ, and Conney AH: Inhibitory effect of curcumin, chlorogenic acid, caffeic acid, and ferulic acid on tumor promotion in mouse skin by 12-O-tetradecanoylphorbol-13-acetate. Cancer Res *48:* 5941-5946, 1988.

14 Singh SV, Hu X, Srivastava SK, Singh M, Xia H, Orchard JL and Zaren HA: Mechanism of inhibition of benzo[a]pyrene-induced forestomach cancer in mice by dietary curcumin. Carcinogenesis *19:* 1357-1360, 1998.

15 Huang MT, Lou YR, Ma W, Newmark HL, Reuhl KR, and Conney AH: Inhibitory effects of dietary curcumin on forestomach, duodenal, and colon carcinogenesis in mice. Cancer Res *54:* 5841-5847, 1994.

16 Tanaka T, Makita H, Ohnishi M, Hirose Y, Wang A, Mori H, Satoh K, Hara A and Ogawa H: Chemoprevention of 4-nitroquinoline 1-oxide-induced oral carcinogenesis by dietary curcumin and hesperidin: comparison with the protective effect of beta-carotene. Cancer Res *54:* 4653-4659, 1994.

17 Rao CV, Rivenson A, Simi B and Reddy BS. Chemoprevention of colon carcinogenesis by dietary curcumin, a naturally occurring plant phenolic compound. Cancer Res *55:* 259-266, 1995.

18 Chuang SE, Ku ML, Hsu CH, Chen CR, Lin JK, Lai GM, Hsieh CY and Cheng AL: Curcumin-containing diet inhibits diethylnitrosamine

– induced mouse hepatocarcinogenesis. Carcinogenesis *21:* 331-335, 2000.

19 Wahlström B and Blennow G: A study on the fate of curcumin in the rat. Acta Pharmacol Toxicol *43:* 83-92, 1978.

20 Ammon HPT and Wahl MA: Pharmacology of *Curcuma longa*. Planta Med *57:* 1-7, 1991.

21 Soni KB and Kuttan R: Effect of oral curcumin administration on serum peroxides and cholesterol level in human volunteers. Indian J Physiol Pharmacol *36:* 273-275, 1992.

22 Cooper TH, Clark G, Guzinski J: In(C.T. Ho (ed), Food Phytochemicals II: Teas, Spices, and Herbs, pp.231-236, American Chemical Society, Washingtor D.C., 1994.

23 Pan MH, Huang TM and Lin JK: Biotransformation of curcumin through reduction and glucuronidation in mice. Drug Meta. Disp *27(1):* 486-494, 1999.

24 Chuang SE, Cheng AL, Lin JK and Kuo ML: Inhibition by curcumin of diethylnitrosamine-induced hepatic hyperplasia, inflammation, cellular gene products and cell-cycle-related proteins in rats. Food Chem Toxicol *38:* 991-995, 2000.

25 Polasa K, Sesikaran B, Krishna TP and Krishnaswamy K: Turmeric (*Curcuma longa*) – induced reduction in urinary mutagen. Food Chem Toxicol *29:* 699-706, 1991.

26 Kawamori T, Lubet R, Steele VE, Kelloff GJ, Kaskey RB, Rao CV and Reddy BS: Chemopreventive effect of curcumin, a naturally occurring anti-inflammatory agent, during promotion/progression stage of colon cancer. Cancer Res *59:* 597-601, 1999.

27 Wahlstrom B and Blennow G: A study on the fate of curcumin in the rat. Acta Pharmacol toxicol *43:* 86-92, 1978.

28 Ravindranath V and Chandrasekhare: Absorption and tissue distribution of curcumin in rats. Toxicol *16:* 259-265, 1980.

Received January 15, 2001
Accepted May 2, 2001